

Case report

Unilateral common carotid artery dissection in a patient with recent COVID-19: An association or a coincidence?



Onur Serdar Gencler^{a,*}, Meltem Refiker Ege^b, Aydın Aslan^c

^a Department of Neurology, Medical Park Ankara Hospital, Yuksek Ihtisas University, Kent Koop District, 1868 Street Batikent Avenue. No:15, Yenimahalle, Ankara 06680, Turkey

^b Department of Cardiology, Medical Park Ankara Hospital, Yuksek Ihtisas University, Kent Koop District, 1868 Street, Batikent Avenue. No:15, Yenimahalle, Ankara 06680, Turkey

^c Department of Radiology, Liv Hospital, Yuksek Ihtisas University, Kavaklidere Avenue Bestekar Road No:8, Cankaya, Ankara 06680, Turkey

ARTICLE INFO

Article history:

Received 3 December 2020

Accepted 13 February 2021

Keywords:

COVID-19

Carotid artery dissection

Ischemic stroke

Thromboinflammatory changes

Vascular complications

ABSTRACT

The “Corona Virus Disease 2019 (COVID-19)”, caused by severe acute respiratory coronavirus 2 (SARS-CoV-2), progressed rapidly since its first outbreak, and quickly developed into a pandemic. Although COVID-19 mostly presents with respiratory symptoms, researchers have started reporting neurologic manifestations such as cerebrovascular diseases in patients, with COVID-19 as the pandemic has progressed. Herein, we report a case of 38-year-old female patient identified with a left common carotid artery dissection, with COVID-19. Clinicians must keep in mind that COVID-19 can cause vascular complications such as carotid artery dissections in the ensuing period, even after the acute phase, although there is currently a lack of sufficient evidence to identify any causal association between COVID-19 and arterial dissections.

© 2021 Elsevier Ltd. All rights reserved.

1. Introduction

Amid the ongoing Corona Virus Disease 2019 (COVID-19) pandemic, caused by severe acute respiratory coronavirus 2 (SARS-CoV-2), although neurological signs and diseases have recently been reported, the disease mostly presents with respiratory symptoms [1]. In a retrospective study focusing on the neurological signs associated with COVID-19, some 5.7% of patients suffering from severe infection were noted to develop cerebrovascular disease (CVD) [2]. Although CVDs are common in the elderly, younger patients with no known risk factors have been presenting with stroke more commonly, since the onset of the COVID-19 pandemic [3,4]. Vascular endothelial dysfunction and coagulopathy have been suggested as possible complications of COVID-19 [3]. The current manuscript presents a case of unilateral common carotid artery (CCA) dissection in a young patient with COVID-19, with, aiming to draw attention to the neurovascular events seen during the COVID-19 pandemic.

2. Case presentation

A 38-year-old female patient presented to the cardiology outpatient clinic with a reported 10-day history of palpitation, shortness

of breath and chest pain. It was understood that the patient had presented to an external facility with complaints of fever and fatigue approximately 1 month earlier, and had received therapy after being diagnosed with COVID-19. The patient's medical history was unremarkable for any systemic disease, smoking or alcohol use; a cardiovascular system examination revealed normal findings; and blood pressure was 110/75 mmHg, pulse was 82 bpm and body temperature was 36.6 °C. A complete blood count and routine blood chemistry showed no abnormalities, and troponin-I was <0.01 ng/mL. An electrocardiogram (ECG) revealed normal sinus rhythm; an exercise ECG recorded no acute ST or ischemia-related changes; and a transthoracic echocardiogram showed no abnormal findings. When the anamnesis detailed, the patient reported pain radiating to the head and the left side of the neck for the last three days that was, gradually increasing in intensity. A computed tomography angiography (CTA) performed on the basis of this indication revealed a focal dissection in the proximal left CCA and an associated focal periarterial hematoma (Fig. 1). The patient was thus sent for a neurological examination, revealing normal findings, while cranial magnetic resonance imaging (MRI) findings were within normal ranges, and a diffusion-weighted cranial MRI showed no acute ischemic lesion. Thereupon, the patient was interrogated again about the etiology of the carotid artery dissection (CAD). The patient had no history of hereditary connective tissue disorder or any recent history of trauma to the head or neck regions. The patient was diagnosed with CCA dissection, and was

* Corresponding author.

E-mail address: serdargencler@gmail.com (O.S. Gencler).

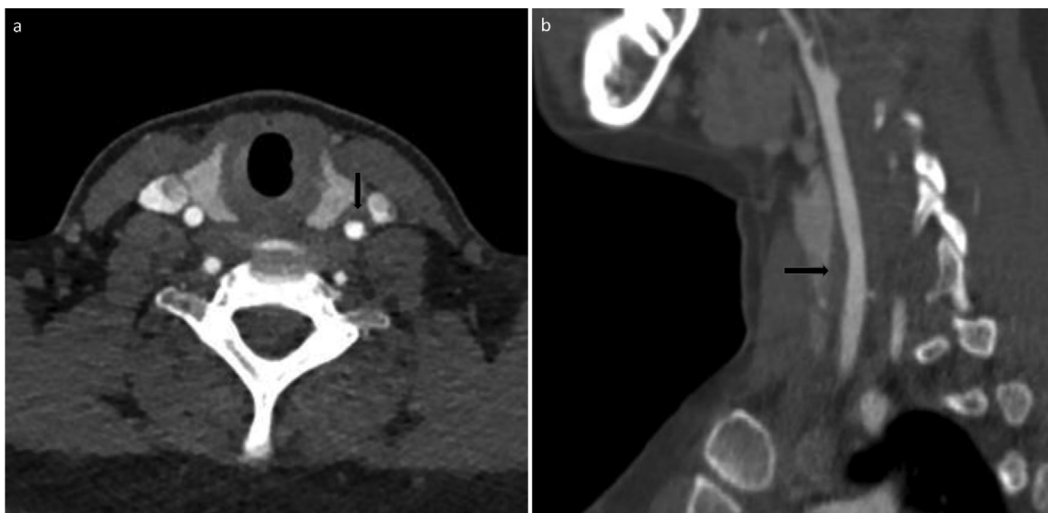


Fig. 1. Focal common carotid artery dissection. Axial (a) and sagittal (b) CT angiography images shows focal periarterial haematoma related to focal dissection (arrows in a and b).

placed on a therapy of low-molecular-weight heparin (LMWH). The patient was switched to oral warfarin therapy and developed no neurological deficits during follow-up, and the ache to the head and neck resolved almost completely. A CTA performed two months after the initial presentation revealed that the periarterial hematoma associated with focal dissection in the left CCA had largely regressed (Fig. 2).

3. Discussion

According to the Global Burden of Disease 2010 study, the approximate global incidence of stroke is 258/100,000/year [5]. Furthermore a systematic review reveals incidences of stroke in young adults in the range of 6.14–48.51/100,000 [6]. Recent studies, on the other hand, report the incidence of stroke among COVID-19 patients to be 0.5–1% [7]. CAD is known to be one of the leading causes of ischemic stroke in young and middle-aged patients [8]. In the case we present here, no anatomical variations or fibromuscular dysplasia [9] that could have caused CAD were detected on CTA. The patient's medical history contained no signs

of connective tissue disorder, no minor traumas to the head or cervical region, and no heavy lifting, violent coughing fits or vomiting that could be involved in a CAD etiology [10,11]. Previous studies have reported that infections during childhood and young adulthood are risk factors for ischemic stroke, while a respiratory system infection such as COVID-19, may be a potential risk factor for spontaneous CAD [10].

Cervical artery dissections [4,12] and spontaneous coronary artery and aortic dissections [13,14] have been reported in patients diagnosed recently with COVID-19, which suggests that COVID-19 may be a trigger factor for CVD. Clinical features such as younger age and lack of any known stroke risk factors may suggest that the strokes detected in patients with a history of COVID-19 may be attributable to SARS-CoV-2 [7]. Such severe conditions as stroke or inflammatory disease may develop in later stages of COVID-19, and even during recovery [15]. On this basis, the temporal association of these two conditions in the present case, and the absence of any other predisposing factors suggests, but cannot prove, that COVID-19 is a triggering factor for CAD. That said, given the large

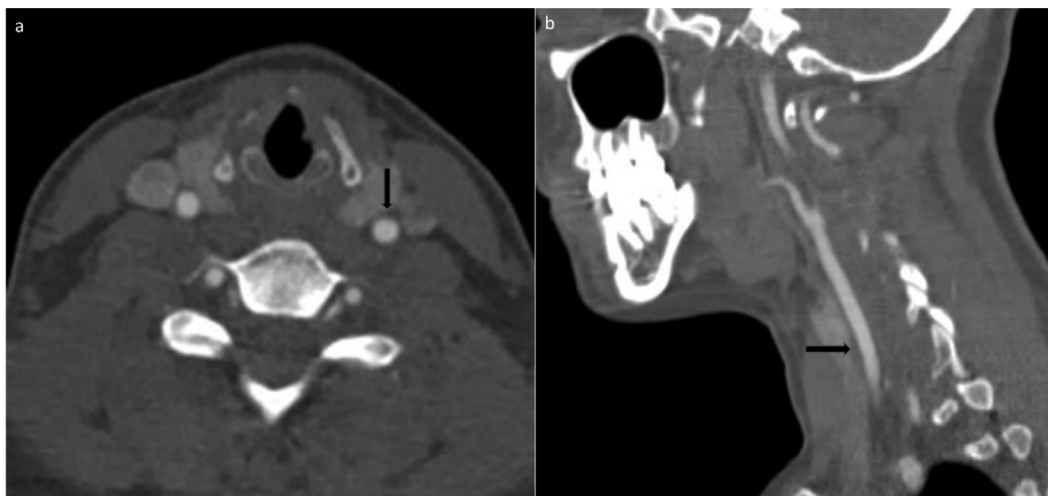


Fig. 2. Two months after focal common carotid artery dissection, it has been showed that the amount of periarterial haematoma related to focal dissection was declined in axial (a) and sagittal (b) CT angiography images (arrows in a and b).

number of infected patients during the COVID-19 pandemic, this association may also be coincidental.

Recent reports have identified the important role played by vascular dysfunction in the COVID-19 pathogenesis [12]. Coronavirus enters cells via the ACE-II receptors and TMPRSS2 proteases, and SARS-CoV-2 is thought to trigger endothelial inflammation, microangiopathy, vasculitis and thrombosis in vascular structures [16]. Viral diseases can lead to impairments in the vascular endothelial, leading to inflammation and associated thrombosis. Hyperinflammatory immune response can arise in SARS-CoV-2, and a cytokine storm can occur secondary to endothelial IL-6 release, bringing about thromboinflammatory changes in the vascular structure and the surrounding tissues [17,18]. Inflammatory cytokines, free oxygen radicals and matrix metalloproteinases degrade the extracellular matrix, leading to vascular wall dysfunction [10,12], with the potential to lead to CAD.

As seen in the present case, CADs can cause moderate to severe acute-onset unilateral head and neck pain that differs in character to previous episodes of pain, but without eliciting focal neurological deficits [8,11]. A CTA or magnetic resonance angiography (MRA) must be performed as soon as the suspicion of such a dissection arises [11].

Anticoagulant or antiaggregant drugs, endovascular therapies and surgery are among the treatment options in CADs, among which, the endovascular treatment options are resorted to if the stenosis persists, despite anticoagulant therapy in appropriate doses, if the dissection progresses or if an aneurysm develops as a complication [8]. The present case responded dramatically to anticoagulant therapy, and so an endovascular procedure was not considered.

4. Conclusion

COVID-19 can be a potential risk factor for CAD, even in young patients at no known risk, although there is currently a lack of sufficient evidence in this regard. As seen in the present case, CADs can be observed in mild cases who recover from COVID-19 without developing a cytokine storm. It must be kept in mind that COVID-19 can cause vascular complications in the ensuing period, even after the acute phase, although long-term case series and studies are required to identify any causal relationship between COVID-19 and CAD.

Disclaimers

None to declare.

Source(s) of support

None to declare.

Declarations of interest

None.

Conflict of interest

All the authors declare no conflict of interest.

References

- [1] Ellul MA, Benjamin L, Singh B, Lant S, Michael BD, Easton A, et al. Neurological associations of COVID-19. *Lancet Neurol* 2020;19(9):767–83. [https://doi.org/10.1016/S1474-4422\(20\)30221-0](https://doi.org/10.1016/S1474-4422(20)30221-0).
- [2] Mao L, Jin H, Wang M, Hu Y, Chen S, He Q, et al. Neurologic manifestations of hospitalized patients with coronavirus disease 2019 in Wuhan, China. *JAMA Neurol* 2020;77(6):683–90. <https://doi.org/10.1001/jamaneurol.2020.1127>.
- [3] Oxley TJ, Mocco J, Majidi S, Kellner CP, Shoirah H, Singh IP, et al. Large-vessel stroke as a presenting feature of Covid-19 in the young. *N Engl J Med* 2020;382(20):. <https://doi.org/10.1056/NEJMc2009787e60>.
- [4] Patel P, Khandelwal P, Gupta G, Singla A. COVID-19 and cervical artery dissection-A causative association? *J Stroke Cerebrovasc Dis* 2020;29(10):. <https://doi.org/10.1016/j.jstrokecerebrovasdis.2020.105047>.
- [5] Feigin VL, Forouzanfar MH, Krishnamurthi R, Mensah GA, Connor M, Bennett DA, et al. Global Burden of Diseases, Injuries, and Risk Factors Study 2010 (GBD 2010) and the GBD Stroke Experts Group. Global and regional burden of stroke during 1990–2010: findings from the Global Burden of Disease Study 2010. *Lancet* 2014;383(9913):245–54. [https://doi.org/10.1016/s0140-6736\(13\)61953-4](https://doi.org/10.1016/s0140-6736(13)61953-4).
- [6] Marini C, Russo T, Felzani G. Incidence of stroke in young adults: a review. *Stroke Res Treat* 2010;2011:1. <https://doi.org/10.4061/2011/535672535672>.
- [7] Tsvigoulis G, Palaodimou L, Zand R, Lioutas VA, Krogias C, Katsanos AH, et al. COVID-19 and cerebrovascular diseases: a comprehensive overview. *Ther Adv Neurol Disord* 2020;13. <https://doi.org/10.1177/1756286420978004>.
- [8] Cai X, Guan J, Ren S, Wei Y, Peng X, Qiu W, et al. Treatment of internal carotid artery dissection with Willis covered stent: a case report of recurrent limb weakness and no response to medical therapy. *Exp Ther Med* 2016;11(5):1983–6. <https://doi.org/10.3892/etm.2016.3112>.
- [9] Demetrius JS. Spontaneous cervical artery dissection: a fluoroquinolone induced connective tissue disorder? *Chiropr Man Therap* 2018;26:22. <https://doi.org/10.1186/s12998-018-0193-z>.
- [10] Campos CR, Bassi TG, Pinto F, Abrahão DK. Internal carotid artery dissection in a patient with recent respiratory infection: case report of a possible link. *Arq Neuropsiquiatr* 2005;63(2B):523–6. <https://doi.org/10.1590/s0004-282x2005000300029>.
- [11] Thomas LC. Cervical arterial dissection: An overview and implications for manipulative therapy practice. *Man Ther* 2016;21:2–9. <https://doi.org/10.1016/j.math.2015.07.008>.
- [12] Morassi M, Bigni B, Cobelli M, Giudice L, Bnà C, Vogrig A. Bilateral carotid artery dissection in a SARS-CoV-2 infected patient: causality or coincidence? *J Neurol* 2020;267(10):2812–4. <https://doi.org/10.1007/s00415-020-09984-0>.
- [13] Albiero R, Seresini G. Atherosclerotic spontaneous coronary artery dissection (A-SCAD) in a patient with COVID-19: case report and possible mechanisms. *Eur Heart J Case Rep* 2020;4(F11):1–6. <https://doi.org/10.1093/ehjcr/ytaa133>.
- [14] Tabaghi S, Akbarzadeh MA. Acute type A aortic dissection in a patient with COVID-19. *Future Cardiol* 2020. <https://doi.org/10.2217/fca-2020-0103>.
- [15] Romero-Sánchez CM, Díaz-Maroto I, Fernández-Díaz E, Sánchez-Larsen Á, Layos-Romero A, García-García J, et al. Neurologic manifestations in hospitalized patients with COVID-19: the ALBACOV registry. *Neurology* 2020;95(8):e1060–70. <https://doi.org/10.1212/WNL.0000000000009937>.
- [16] Singh TM, Lee A, Vo M, Ali SF, Cheon BM, Josephson M, et al. Urgent carotid endarterectomy in a COVID-19 patient: standard approach with some adjustments. *Vascular Dis Manage* 2020;17(5):E104–9.
- [17] Ahmed S, Zimba O, Gasparyan AY. Thrombosis in Coronavirus disease 2019 (COVID-19) through the prism of Virchow's triad. *Clin Rheumatol* 2020;39(9):2529–43. <https://doi.org/10.1007/s10067-020-05275-1>.
- [18] Colling ME, Kanthi Y. COVID-19-associated coagulopathy: an exploration of mechanisms. *Vasc Med* 2020;25(5):471–8. <https://doi.org/10.1177/1358863X20932640>.